

A Randomized Controlled Trial to Evaluate Different Treatment Regimes with Topical Wound Oxygen (TWO₂) on Chronic Wounds

Aburto I¹, Frye C²

¹ Instituto Nacional de Heridas (INH), Santiago, Chile, ² AOTI Ltd., Galway, Ireland

Introduction

Chronic wounds on the lower leg and foot are frequent, difficult to treat and show high rates of complications⁽¹⁾. After very positive results with a unique pressurized topical oxygen therapy (TWO₂) device in other studies^(2,3) we investigated whether 4 weeks of TWO₂ treatment and consecutive 8 weeks of advanced moist wound treatment (AMWT) is equally effective in healing chronic wounds as continuous treatment with TWO₂.

Method

The randomized, controlled study was conducted at the National Wound Institute in Santiago de Chile. In an outpatient setting with patients with severe diabetic foot ulcers (DFU) (n=20) and chronic venous ulcers (CVU) (n=20) all patients received TWO₂ for a period of one month. Then the groups were randomized to continue with TWO₂ (TWO₂-TWO₂ group) or receive AMWT for 2 more month (TWO₂-AMWT group). TWO₂ patients were treated daily for 2 hours 5 times a week. The device delivered humidified medical grade oxygen with pressure cycles between 5 and 50 mbar. Dressing changes in the control group were performed according to best practice at a minimum of twice a week. The primary endpoint was complete ulcer closure after 90 days.

Results

The majority (82%) of the patients were referred to the study center for minor or major amputation. All of these patients improved under the therapy and no patient underwent amputation. Patients were comparable concerning age, size of the wound and duration of the wound. 90% of the DFU patients in the TWO₂-TWO₂ group healed within 90 days vs. 40% in the TWO₂-AMWT group. Patients with CVU had 50% healing vs. 30%, respectively.

Conclusion

Patients with complicated ulcers benefit from the treatment of topical localized oxygen (TWO₂). Continuous TWO₂ treatments for 12 weeks showed significant better outcomes than a shorter TWO₂ treatment regime of 4 weeks followed by AMWT.

Figure 1: Number of closed wounds in different ulcers in TWO₂ group and control group

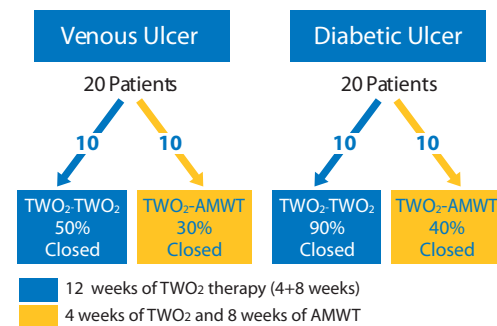


Figure 2: Reusable TWO₂ extremity chamber



- 1) Boulton AJ, Vileikyte L, Ragnarson-Tennvall G, Apelqvist J. The global burden of diabetic foot disease. Lancet. 2005; 336: 1719-1724.
- 2) Scott, G and Reeves, R. Topical Oxygen Alters Angiogenesis Related Growth Factor Expression in Chronic Diabetic Foot Ulcers. Poster Presentation. 2005: Symposium on Advanced Wound Care.
- 3) Tawfik W and Sultan S. Does Topical Wound Oxygen (TO) Offer an Improved Outcome Over Conventional Compression Dressings (CCD) in the Management of Refractory Venous Ulcers (RVU). A Parallel Observational Comparative Study. Eur J Vasc Endovasc Surg. 2009 May 21, 125-32